

# A case of septic pulmonary embolism associated with hand sepsis in an immunocompetent host

**To the editor:** Septic pulmonary embolism (SPE) occurs when septic material aggregates in the pulmonary circulation from an extrapulmonary infective focus, resulting in substantial clinical symptoms. The common sources of SPE include skin and soft-tissue infection, intravascular catheters, infective endocarditis, liver or kidney abscess, septic thrombophlebitis, Lemierre's syndrome, use of intravenous drugs, and periodontal infection.

A 25-year-old man, HIV negative and a self-reported methamphetamine (tik) and methaqualone (Mandrax) user, with no medical history, was referred to our emergency department by his primary care doctor because of swelling and erythema of the little finger of his left hand for 5 days before presentation.

On examination, he was conscious and febrile, appeared toxic with a heart rate of 119 bpm, and was normotensive (blood pressure 120/70 mmHg) with a respiratory rate of 28/min and oxygen saturation of 96%. Arterial blood gas analysis (room air) showed arterial partial pressure of oxygen 10 kPa, partial pressure of carbon dioxide 5.37 kPa, oxygen saturation 94.8% and pH 7.406. The chest had bilateral crepitations. On local examination, there was severe paronychia with dorsal tissue necrosis, erythema, and oedema up to the 7th extensor compartment of the dorsum of the hand. The sensation of the finger pulp remained intact.

Laboratory investigations revealed haemoglobin 15 g/dL, total leucocyte count  $18.8 \times 10^9/L$  (neutrophils 38%), C-reactive protein 131 mg/L, serum sodium 129 mmol/L and serum potassium 5.1 mmol/L. The results of liver and kidney function tests were normal. Wound and blood cultures grew *Staphylococcus aureus*. No growth was seen on tracheal and urine cultures.

Imaging of the hand showed soft-tissue swelling with a subtle periosteal reaction (Fig. 1A).

The patient was taken to theatre for surgical debridement under regional anaesthesia with a Bier block, and deep tissue samples were taken and sent for microbiological testing. Based on culture sensitivity, intravenous cloxacillin 2 g 6-hourly was commenced immediately, and the wound was allowed to heal by secondary intention with appropriate dressings. However, he continued to have spikes of high-grade fever with rigors and complained of pleuritic chest pain and minor haemoptysis.

A chest radiograph (Fig. 1B) showed multiple nodules, some of which were cavitating. At this stage, both community-acquired pneumonia and cavitating malignancy were in the differential diagnosis, together with COVID-19 pneumonia, as it was during the height of the COVID-19 pandemic. An abdominal ultrasound scan ruled out any abdominal sources of sepsis or underlying malignancy.

Computed tomography (CT) pulmonary angiography (Fig. 1C) revealed innumerable bilateral randomly distributed, well-defined and variably sized cavitary nodular lesions in keeping with SPE. There were no radiological or laboratory findings of COVID-19. Findings on echocardiography were normal with no features of infective endocarditis. The patient continued to receive intravenous cloxacillin and supportive care in the surgical ward for 2 more weeks and was discharged after a total stay of 4 weeks. His progress was satisfactory on follow-up in the outpatient department.

SPE is an uncommon form of lung disease that develops when a thrombus containing micro-organisms embolises into the veins, circulates to the heart and lodges in the pulmonary arteries, causing infection, infarction, and bilateral nodules and/or cavities in the lung parenchyma.<sup>[1]</sup> Insidious onset of fever, shortness of breath, cough, haemoptysis, and chest pain associated with pulmonary infiltrates are the most common clinical presentations of patients with SPE.<sup>[2]</sup>

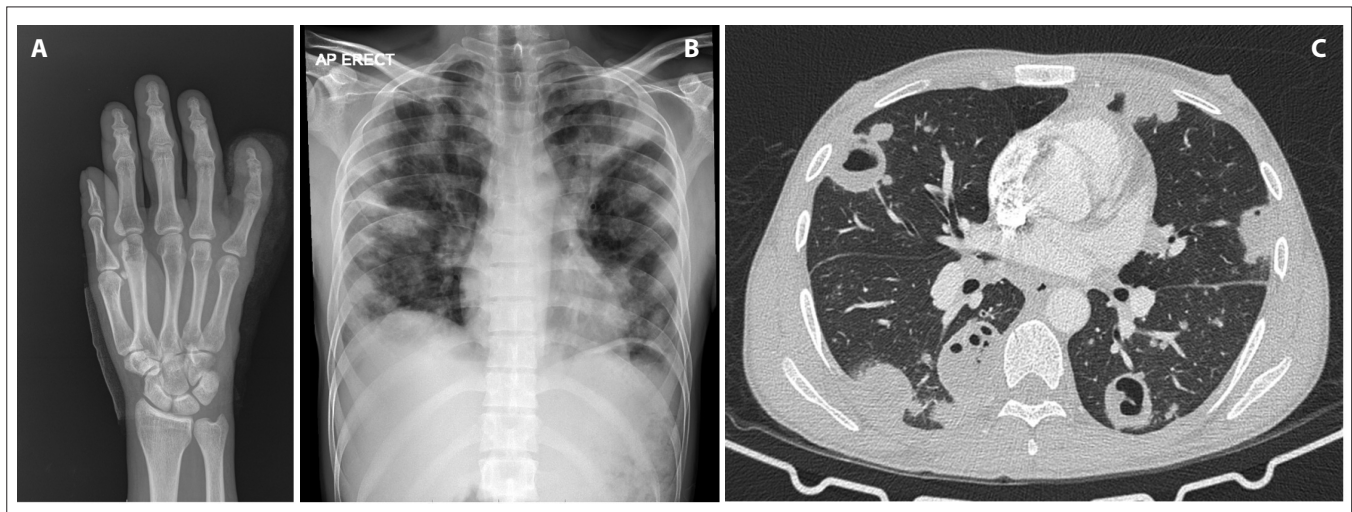


Fig. 1. (A) Frontal radiograph of the hand demonstrating subtle irregularity of the medial cortex, periosteal reaction and soft-tissue swelling around the distal phalange of the left little finger. There is no associated joint effusion, foreign body or fracture. (B) Frontal chest radiograph showing innumerable cavitary pulmonary lesions with no zonal predilection. (C) Axial computed tomography scan of the chest in lung window confirms multiple air- and fluid-filled cavitary lesions randomly distributed within the pulmonary parenchyma.

Depending on the embolic source, SPE can be classified as cardiac, peripheral endogenous or exogenous, each manifesting in different epidemiological and clinical ways.<sup>[3]</sup> The most common causative organisms of SPE are methicillin-susceptible *S. aureus* (32%), methicillin-resistant *S. aureus* (18%), fusobacteria (7%), *Klebsiella* (7%) and *Candida* (4%) species, and *Streptococcus viridans* (3%).<sup>[4]</sup> SPE has a high mortality rate and remains a diagnostic challenge in clinical practice because of its nonspecific clinical manifestations and life-threatening complications.<sup>[3]</sup>

The diagnosis of SPE is usually suggested by the presence of a predisposing factor, febrile illness, and CT findings of multiple randomly distributed nodular lung infiltrates, with or without cavitation. The feeding vessel sign on the CT chest scan is highly suggestive and has been reported in both uncomplicated pulmonary emboli and pulmonary metastases, and simply indicates the haematogenous origin of the parenchymal nodule.<sup>[5]</sup> Our patient had a febrile illness and an extrapulmonary source of infection, and *S. aureus* was isolated both from the wound and on blood culture, making SPE the main consideration in the differential diagnosis of cavitating pulmonary nodules. The presence of *S. aureus* bacteraemia is consistent with previous findings in a South African study by Meel and Essop,<sup>[6]</sup> which showed that *S. aureus* is the most common organism isolated. Interestingly, they highlighted that SPE was common in intravenous recreational drug users, although our patient smoked drugs rather than injecting intravenously. Echocardiography is an important diagnostic modality to exclude infective endocarditis in patients with *S. aureus* bacteraemia, as in our case, because infective endocarditis is one of the major causes of SPE.

Management of SPE comprises prompt administration of appropriate antibiotic therapy for 4 - 6 weeks and control of infectious sources, along with surgical debridement and supportive care.<sup>[1]</sup>

In conclusion, an early diagnosis of SPE is the key to improving patient outcomes, and clinicians should be aware of radiological findings in SPE, which serve as an invaluable diagnostic tool.

**T Zobair**, MB ChB, MD, Cert Pulmonology (SA), MPhil (Pulm)  
Division of Pulmonology, Faculty of Health Sciences, University of Cape Town and Groote Schuur Hospital, Cape Town, South Africa  
dr.tarig@hotmail.com

**I Sihlahla**, MB ChB, MMed (Rad), FC Rad (SA)  
Division of Radiology, Faculty of Health Sciences, University of Cape Town and Groote Schuur Hospital, Cape Town, South Africa

**D B Arnolds**, MB ChB, MMed (Orth), FCS Orth (SA)  
Division of Orthopaedic Surgery, Faculty of Health Sciences, University of Cape Town and Groote Schuur Hospital, Cape Town, South Africa

**R I Raine**, MB ChB, MMed (Med), FCP (SA)  
Division of Pulmonology, Faculty of Health Sciences, University of Cape Town and Groote Schuur Hospital, Cape Town, South Africa

**G Calligaro**, BSc Hons (Phys), MB ChB, FCP (SA), MMed (Med), Cert Pulmonology (SA)  
Division of Pulmonology, Faculty of Health Sciences, University of Cape Town and Groote Schuur Hospital, Cape Town, South Africa

1. Cook RJ, Ashton RW, Aughenbaugh GL, Ryu JH. Septic pulmonary embolism: Presenting features and clinical course of 14 patients. *Chest* 2005;128(1):162-166. <https://doi.org/10.1378/chest.128.1.162>
2. Jiang J, Liang Q-L, Liu L-H, et al. Septic pulmonary embolism in China: Clinical features and analysis of prognostic factors for mortality in 98 cases. *BMC Infect Dis* 2019;19(1):1082. <https://doi.org/10.1186/s12879-019-4672-1>
3. MacMillan JC, Milstein SH, Samson PC. Clinical spectrum of septic pulmonary embolism and infarction. *J Thorac Cardiovasc Surg* 1978;75(5):670-678.
4. Ye R, Zhao L, Wang C, et al. Clinical characteristics of septic pulmonary embolism in adults: A systematic review. *Respir Med* 2014;108(1):1-8. <https://doi.org/10.1016/j.rmed.2013.10.012>
5. Kuhlman JE, Fishman EK, Teigen C. Pulmonary septic emboli: Diagnosis with CT. *Radiology* 1990;174(1):211-213. <https://doi.org/10.1148/radiology.174.1.2294550>
6. Meel R, Essop MR. Striking increase in the incidence of infective endocarditis associated with recreational drug abuse in urban South Africa. *S Afr Med J* 2018;108(7):585-589. <https://doi.org/10.7196/SAMJ.2018.v108i7.13007>

Received 23 April 2023. Accepted 25 March 2024. Published 4 July 2024.

*Afr J Thoracic Crit Care Med* 2024;30(2):e1014. <https://doi.org/10.7196/AJTCCM.2024.v30i2.1014>