

Tracheal necrosis after sandwich immunotherapy and stereotactic body radiotherapy for lung cancer

To the editor: Stereotactic body radiotherapy (SBRT) offers small fractions of focused high-dose radiation to a targeted lesion with high accuracy.^[1] Excellent local tumour control with minimal normal tissue toxicity can be achieved with SBRT. However, despite accurate targeting, normal tissues near the tumour can receive higher doses of radiation than with standard treatment, which can cause harm if the structures are exceptionally radiosensitive. In central airway-located lesions, particularly in the ‘no-fly zone’, defined as a 2 cm radius around the proximal bronchial tree, the chances of SBRT toxicity to adjacent structures are therefore relatively high, especially with higher radiation doses.^[2,3] One of the significant airway complications of SBRT is airway necrosis with or without stenosis, strictures or fistulas.^[4] We present a case of stage IV squamous cell lung cancer in which tracheal necrosis developed after SBRT.

A 70-year-old man, an ex-smoker, was diagnosed in late 2020 with squamous cell carcinoma of the lung, stage IVA (cT2a N1 M1b). A positron emission tomography-computed tomography (PET-CT) scan showed intense fluorodeoxyglucose uptake in a large right upper lobe lesion and focal intense uptakes in a few nodules in the superior and apical segments of the right lower and left upper lobes, respectively. A percutaneous core biopsy specimen from the right upper lobe lesion showed poorly differentiated carcinoma with squamous morphology, and immunohistochemistry confirmed squamous cell carcinoma of the lung. The patient had no driver mutations on the comprehensive genomic molecular profile, and the programmed cell death ligand 1 (PD-L1) tumour proportion score was 90%. He therefore received four cycles of palliative chemoimmunotherapy with carboplatin (area under the curve 5) every 3 weeks, nab-paclitaxel 100 mg/m² on days 1, 8 and 15, plus pembrolizumab 200 mg every 3 weeks for four cycles with an excellent partial response. He was subsequently continued on maintenance pembrolizumab every 6 weeks. However, regional nodal oligometastatic lesions were detected in the right lower paratracheal lymph nodes after 12 months at follow-up PET-CT. The patient was offered SBRT, a total dose of 60 Gy in eight fractions, in late 2021. Subsequent imaging showed a complete response, so pembrolizumab was continued.

Fourteen months later, in February 2023, the patient presented with a cough and mild haemoptysis of 1 month’s duration. The cough was dry and did not respond to symptomatic measures. He did not have other symptoms and was feeling well otherwise. On examination, he was stable and was not in respiratory distress. His vital signs were within normal limits. Oxygen saturation was 96% on room air. The sputum looked yellowish and was stained with blood. Chest examination was unremarkable, with normal breath sounds bilaterally. Routine laboratory values were within normal limits. A CT scan of the chest showed a subtle disruption in the wall of the medial aspect of the lower part of the trachea with loss of the C-shaped tracheal cartilage (Fig. 1A). Bronchoscopy showed a focal area of inflamed mucosa lined by a thick layer of yellowish secretions/crust on the right anterolateral wall of the lower trachea just above the carina (Fig. 1B). Multiple biopsies were

taken. Histopathological examination revealed granulation tissue with necrosis and destruction of the cartilage and a few bacterial colonies in the background (Fig. 1C). There was no growth in

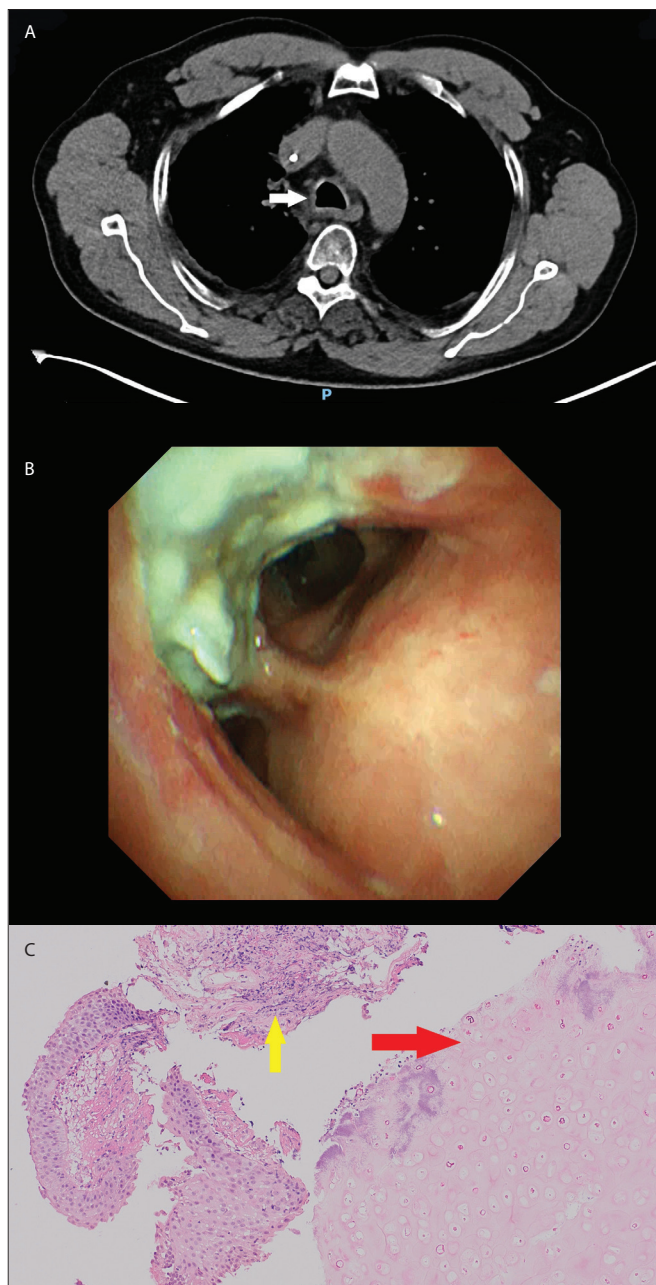


Fig. 1. (A) Computed tomography scan of the chest, soft-tissue view, showing disruption of the medial aspect of the lower part of the trachea with loss of the C-shaped tracheal cartilage (arrow). (B) Focal area of creamy-coloured mucosa in the right anterolateral wall of the lower trachea just above the carina. (C) Histopathology specimen demonstrating necrotic cartilage (red arrow), inflammatory granulation tissue (yellow arrow) and bronchial epithelium (H&E \times 200).

fungal and tuberculosis cultures of the biopsy sample, while the bacterial culture grew *Corynebacterium amycolatum*, which is commonly found in the normal microbiome of the human skin and mucosal membranes. However, it has been regarded as a potential opportunistic pathogen in immunocompromised patients.^[5] Multidisciplinary team discussion favoured a diagnosis of tracheal necrosis with superimposed infection based on the clinical and pathological features, and the patient was therefore treated with broad-spectrum antibiotics for 4 weeks. He had an excellent clinical response and reported no more cough or haemoptysis on follow-up at 8 weeks. Bronchoscopy was not repeated, as he was asymptomatic and had returned to normal activities. He also completed 35 cycles of pembrolizumab and has since been in remission.

Tracheal necrosis is a rare condition that can occur in immunocompromised patients, usually due to an infective aetiology, including fungal infections such as *Aspergillus* and infections with bacterial organisms such as *Actinomyces*. Other causes include tracheostomy, neck surgery and radiation.^[6-8] Airway damage due to SBRT is a late complication, usually occurring after months of treatment.^[9] The pathogenesis of airway necrosis is not well understood, but it seems that the radiation causes direct damage to the wall of the airways, leading to necrosis and subsequent fibrosis. A protracted fractionation scheme is therefore advised for treating centrally located tumours to avoid these complications. Patients who received concurrent antivasculature growth factor therapy were found to have an increased risk of post-SBRT toxicity.^[10] Possible associations between SBRT-induced pneumonitis and immune checkpoint inhibitors have been reported.^[11,12] Whether immune checkpoint inhibitors contributed to the SBRT-induced tracheal injury in our patient needs to be discussed, especially as the dose was delivered during a longer time frame, eight fractions, to reduce the chances of late toxicity in this no-fly zone.

The radiological findings in tracheal necrosis can be subtle, and bronchoscopy is often required to confirm the diagnosis. The bronchoscopic finding of a focal yellowish thick crusty lining is nonspecific for necrotising tracheitis and can be seen in endobronchial tuberculosis, invasive fungal infections, primarily *Aspergillus* or *Candida*, and infections due to other bacteria, including *Staphylococcus aureus* and *Haemophilus influenzae*. It occurs less commonly in viral infections such as herpes simplex, cytomegalovirus and influenza B, and sometimes in inflammatory lesions secondary to systemic illness such as ulcerative colitis. Cultures from our patient's bronchoscopy specimens were not definitive, the biopsy specimen showing only destruction and granulation without any evidence of malignant spread. The diagnosis is usually made at an advanced stage with significant tissue damage and anatomical distortion.

In conclusion, despite advances in interventional pulmonology, treating complications such as anatomical deformations, strictures and fistulas can be challenging. Hyperbaric oxygen therapy, local debridement and antibiotics in combination have been used successfully to treat complicated tracheal radionecrosis.^[13] The mainstay of treatment is still a conservative approach. However, surgery for tracheal necrosis can be offered on a case-by-case basis. In airway stenosis and strictures, balloon dilatation with or without airway stenting can also be considered.

S M Bennji, MB ChB, MMed (Int), FCP (SA), Cert Pulmonology (SA), MPhil (Pulm), Dip (ERS)^{ORCID}
Thoracic Oncology, Sultan Qaboos Comprehensive Cancer Care and Research Centre, Muscat, Oman
saminj12@gmail.com

B Jayakrishnan, BSc, MBBS, MD, DTCD, DNB, MRCP, FRCP, FCCP, FICS
Thoracic Oncology, Sultan Qaboos Comprehensive Cancer Care and Research Centre, Muscat, Oman

Z Al-Hashami, MD, FRCP
Thoracic Oncology, Sultan Qaboos Comprehensive Cancer Care and Research Centre, Muscat, Oman

L Mula-Hussain, MB ChB, MSc, EF, FRCP (Edin)
Radiation Oncology, Sultan Qaboos Comprehensive Cancer Care and Research Centre, Muscat, Oman

R B Telugu, MBBS, MD, DipRCPath
Onco-Pathology, Sultan Qaboos Comprehensive Cancer Care and Research Centre, Muscat, Oman

- Lo SS, Fakiris AJ, Chang EL, et al. Stereotactic body radiation therapy: A novel treatment modality. *Nat Rev Clin Oncol* 2010;7(1):44-54. <https://doi.org/10.1038/nrclinonc.2009.188>
- Timmerman R, McGarry R, Yiannoutsos C, et al. Excessive toxicity when treating central tumors in a phase II study of stereotactic body radiation therapy for medically inoperable early-stage lung cancer. *J Clin Oncol* 2006;24(30):4833-4839. <https://doi.org/10.1200/JCO.2006.07.5937>
- Lindberg K, Onjukka E. Medical consequences of radiation exposure of the bronchi – what can we learn from high-dose precision radiation therapy? *J Radiol Prot* 2021;41(4). <https://doi.org/10.1088/1361-6498/ac28ef>
- Song SY, Choi W, Shin SS, et al. Fractionated stereotactic body radiation therapy for medically inoperable stage I lung cancer adjacent to central large bronchus. *Lung Cancer* 2009;66(1):88-93. <https://doi.org/10.1016/j.lungcan.2008.12.016>
- Jesus HNR, Rocha DJPG, Ramos RTJ, et al. Pan-genomic analysis of *Corynebacterium amycolatum* gives insights into molecular mechanisms underpinning the transition to apathogenic phenotype. *Front Microbiol* 2022;13:1011578. <https://doi.org/10.3389/fmicb.2022.1011578>
- Aerni MR, Parambil JG, Allen MS, Utz JP. Nontraumatic disruption of the fibrocartilaginous trachea: Causes and clinical outcomes. *Chest* 2006;130(4):1143-1149. <https://doi.org/10.1378/chest.130.4.1143>
- Louie BH, Stramiello J, Senyei G, et al. Necrotizing tracheitis complicated by tracheal wall perforation. *Ear Nose Throat J* 2022;101(10_Suppl):26S-29S. <https://doi.org/10.1177/01455613221123664>
- Warrior K, Pandya S, Tran B. Tracheal necrosis: A pathologic mediastinal window. *Am J Respir Crit Care Med* 2017;195:A6043. https://www.atsjournals.org/doi/abs/10.1164/ajrccm-conference.2017.195.1_MeetingAbstracts.A6043 (accessed 8 May 2024).
- Corradetti MN, Haas AR, Rengan R. Central-airway necrosis after stereotactic body-radiation therapy. *N Engl J Med* 2012;366(24):2327-2329. <https://doi.org/10.1056/nejmc1203770>
- Haseltine JM, Rimmer A, Gelblum DY, et al. Fatal complications after stereotactic body radiation therapy for central lung tumors abutting the proximal bronchial tree. *Pract Radiat Oncol* 2016;6(2):e27-e33. <https://doi.org/10.1016/j.prrro.2015.09.012>
- Louvel G, Bahleda R, Ammari S, et al. Immunotherapy and pulmonary toxicities: Can concomitant immune-checkpoint inhibitors with radiotherapy increase the risk of radiation pneumonitis? *Eur Respir J* 2018;51(1):1701737. <https://doi.org/10.1183/13993003.01737-2017>
- Tian S, Switchenko JM, Buchwald ZS, et al. Lung stereotactic body radiation therapy and concurrent immunotherapy: A multicenter safety and toxicity analysis. *Int J Radiat Oncol Biol Phys* 2020;108(1):304-313. <https://doi.org/10.1016/j.ijrobp.2019.12.030>
- Ariza-Prata M, Morales A, Grajeda J, et al. Successful healing of tracheal radionecrosis: Role of hyperbaric oxygen therapy. *Chest* 2016;150(6):e147-e150. <https://doi.org/10.1016/j.chest.2016.03.027>

Received 18 October 2023. Accepted 25 March 2024. Published 4 July 2024.

Afr J Thoracic Crit Care Med 2024;30(2):e1620. <https://doi.org/10.7196/AJTCCM.2024.v30i2.1620>