

# What potentially treatable opportunistic mould could be the cause of the patients' breathlessness?

S Brunke, MB ChB (Stell); L D Hunter, MB ChB (Stell) PhD; A T Mnguni, MB ChB (UCT), MMed (Int), FCP (SA), Cert Pulmonology (SA) Phys

Department of Internal Medicine, Khayelitsha District Hospital and Faculty of Health Sciences University of Stellenbosch. Western Cape, South Africa

Corresponding author: S Brunke (stef.brunke@outlook.com)

A 50-year-old male with advanced HIV infection and previously treated pulmonary tuberculosis (TB) presented to hospital with a nine-month history of constitutional symptoms, non-productive cough, and worsening dyspnea. Multiple sputa samples over the preceding nine months were culture-negative for TB.

A chest radiograph revealed an ill-defined opacity in the right upper lobe with associated pleural thickening (Fig. 1). Computer-tomography chest imaging demonstrated a cavity in the right upper lobe with associated intracavitary lesions (Fig. 2). The clinical history and radiological findings were consistent with a diagnosis of chronic cavitary pulmonary aspergillosis (CCPA).<sup>[1]</sup> Blood serology and a fungal culture of sputa confirmed both exposure and active growth of *Aspergillus fumigatus*.

After an initial two-week regimen of intravenous *Amphotericin B* the patient was commenced on long-term oral voriconazole therapy.

At a six-week follow up, he reported significant resolution of his constitutional symptoms and radiological improvement was seen on a repeat chest radiograph. Close clinical follow up is planned.

1. Denning DW, Cadranel J, Beigelman-Aubry C. Chronic pulmonary aspergillosis: rationale and clinical guidelines for diagnosis and management. *European Respiratory J* 2015;47(1):45-68. <https://doi.org/10.1183/13993003.00583-2015>.

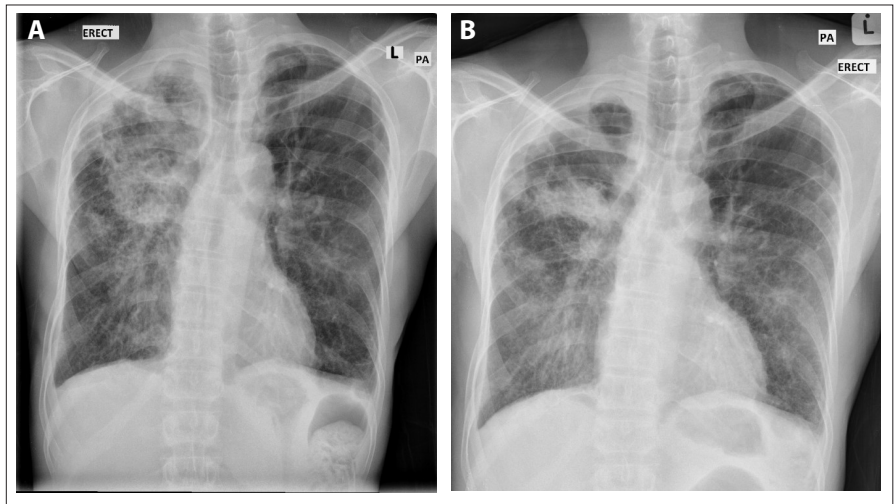


Fig. 1 (A). Chest radiograph on admission to hospital and (B) Follow-up imaging after six weeks of voriconazole therapy.

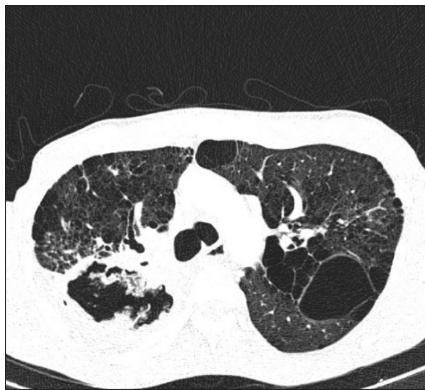

Fig. 2. Computer-tomography chest imaging demonstrating a cavity in the right upper lobe with associated intra-cavity lesion.