

Primary cutaneous melioidosis - A rare case needing intensive care unit admission

S Tripathy,¹ MBBS, MD, PDCC ; S Pal,² MBBS, MD, PDCCv; S Gutte,³ MBBS, MD, DM 

¹ Department of Microbiology, Sanjay Gandhi Post Graduate Institute of Medical Sciences, Lucknow, India

² Department of Microbiology, Santinikentan Medical College, Bolpur, West Bengal, India

³ Department of Critical Care Medicine, Sanjay Gandhi Post Graduate Institute of Medical Sciences, Lucknow, India

Corresponding author: S Gutte (shreyasgutte101@gmail.com)

Background. Melioidosis cases are increasing in Southeast Asia, posing a significant challenge owing to the rising number of diabetic and immune-compromised patients. Pneumonia is the most common presentation of melioidosis, while cutaneous melioidosis is rare.

Objective. We report a case of primary cutaneous melioidosis (PCM) that eventually required intensive care unit (ICU) management.

Method. We describe the case of a 33-year-old male with uncontrolled diabetes mellitus who initially presented with a skin lesion, which was followed by gradual multiorgan involvement diagnosed as melioidosis based on culture-positive results from blood and synovial fluid, and needed ICU admission.

Results. He was successfully treated with intravenous antibiotics and invasive mechanical ventilation after ICU admission.

Conclusion. Cutaneous melioidosis can lead to ICU admission and, if untreated, has a high fatality rate. Faster diagnostic methods like VITEK 2 Compact and MALDI TOF substantially reduce delays in initiating required treatment.

Keywords. Primary cutaneous melioidosis, burkholderia pseudomallei, MALDI-TOF, diabetes.

South Afr J Crit Care 2024;40(2):e1362. <https://doi.org/10.7196/SAJCC.2024.v40i2.1362>

Contribution of the study

Our study emphasize on the need of considering Melioidosis as a possible differential diagnosis, as in lower middle income countries (LMIC) where it can be a frequent cause of multiorgan involvement due to tropical environment and diagnostic resource limitations.

In India, melioidosis cases have increased in recent years, presenting with a myriad of signs and symptoms, such as pneumonia, sepsis, arthritis, abscess and cutaneous manifestations.^[1] A high index of suspicion and awareness among clinicians and microbiologists is essential for an early diagnosis. Rapid identification and management are crucial for patient survival. The case fatality rate of untreated melioidosis can be as high as 49%.^[2] In a study by Pitman *et al.*,^[3] ~22% of patients required intensive care unit (ICU) admission, and 15% experienced septic shock. These data were obtained from culture-confirmed melioidosis cases registered in their database. The severity of the disease depends on the patient's health condition, associated comorbidities, mode of infection and bacterial dose. Here, we report a case of primary cutaneous melioidosis (PCM) that eventually required ICU management.

Case

A 33-year-old businessman with a history of alcohol use disorder initially developed a small furuncle on the left para-median area of the abdomen. The furuncle gradually enlarged and eventually became an ulcer (Fig. 1A). He also experienced diffuse dull abdomen discomfort and lower back pain, followed by bilateral knee joint discomfort and swelling. The patient sought medical attention on the 9th day of illness, in early September. Non-contrast computed tomography (NCCT) of the abdomen on the 10th day of illness (DOI 10) revealed multiple liver abscesses, the largest measuring 2.2 x 2.2 cm in segment 4a

(Fig. 1B). Magnetic resonance imaging (MRI) of the right knee joint was suggestive of mild effusion and osteomyelitis of the femur and tibia (Fig. 1C). Subsequently, the right knee joint was aspirated, and the synovial fluid was sent for bacterial culture. He was empirically started on intravenous piperacillin-tazobactam. At this point, he was also diagnosed with uncontrolled diabetes (HbA1c level 9.4). His back pain gradually increased in severity, accompanied by fever and anorexia. The patient then started developing shortness of breath (DOI 20) and was immediately transferred to the ICU. A high-resolution computed tomography (HRCT) of the thorax was performed (DOI 20). It revealed multiple conglomerate nodules, with a peri-bronchovascular and peripheral distribution, a tree-in-bud pattern, non-homogenous geographic opacities and an air bronchogram in both lower lobes (Fig. 1D). After failed non-invasive ventilation therapy, intubation was performed. Blood cultures grew *Burkholderia pseudomallei*, which was identified by the VITEK 2 (bioMerieux's, USA) automated compact system (DOI 21). Also, synovial fluid aspirated grew *Burkholderia* spp (DOI 23). The identification was confirmed using matrix-assisted laser desorption ionisation time-of-flight mass spectrometry (MALDI TOF). The patient was started on intravenous meropenem, doxycycline and cotrimoxazole based on the sensitivity report. There was a slow but gradual improvement, and he was extubated on DOI 27 and discharged on DOI 42 with oral co-trimoxazole, advised to be continued for 6 months.

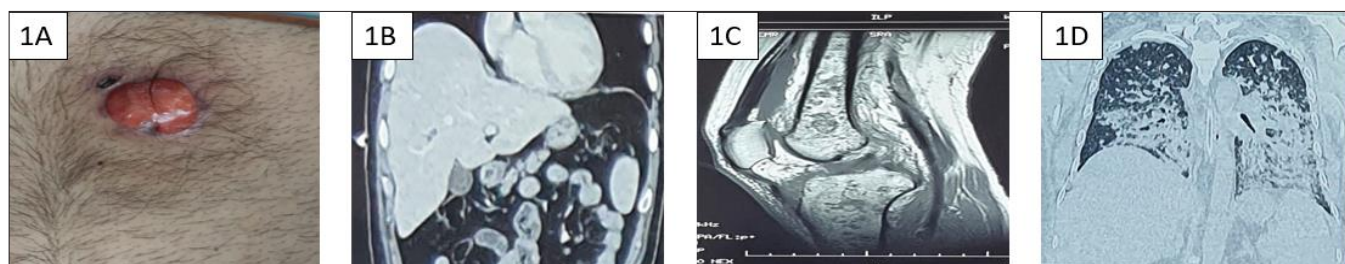


Fig. 1. A. Ulcerated wound on anterior abdomen. B. Non-contrast computed tomography showing multiple liver abscess. C. Magnetic resonance imaging of right knee joint showing osteomyelitis of tibia, femur and synovial fluid collection. D. High-resolution computed tomography showing multiple conglomerate nodules in bilateral lung fields.

Discussion

The *Burkholderia* species, an environmental organism commonly found in soil and water, includes *B. pseudomallei*, the predominant cause of melioidosis in Thailand and Northern Australia, often associated with agrarian activities. The estimated global burden of melioidosis in 2019, measured using disability-adjusted life-years (DALYs), was 4.64 million,^[4] with over 165 000 cases occurring annually.^[5] Despite this, melioidosis is an underdiagnosed disease, and its prevalence is presumably higher than reported.^[6] The full extent of the bacteria's impact remains unknown.

Clinical presentation generally occurs after infection through inhalation, leading to septicaemia, and less commonly through direct cutaneous inoculation.^[7,8] Inhalational exposure results in a shorter incubation period and generally more severe illness, often leading to dissemination following primary pulmonary involvement. PCM has a longer incubation period, is less severe and generally localised to the skin. The present case represents melioidosis with primary cutaneous infection followed by systemic involvement of the joints, liver and respiratory system, ultimately requiring ICU admission.

To the best of our knowledge, there are no reported cases of PCM requiring ICU admission. A review by Fertitta *et al.*^[9] revealed common extra-cutaneous sites involved in PCM, with pulmonary involvement being the more common, followed by osteoarticular. Most of the studies on melioidosis focus on the difference in the occurrence between travellers and non-travellers. However, no such difference in PCM was noted by Fertitta *et al.*^[9] Among their study cohort, PCM was diagnosed in 38 patients; 13 (34.2%) had associated bacteraemia but no hepatic involvement was noted. In our case, there was bacteraemia, hepatic abscesses, septic arthritis and lung involvement following PCM. The synovial fluid and blood culture were positive for *B. pseudomallei*.

Risk factors for melioidosis include diabetes, chronic renal disease, older age, occupational exposure to muddy soil, alcoholism, travel to endemic regions, thalassaemia, chronic lung disease, cystic fibrosis, malignancy and non-HIV-related immune compromise.^[5,6] The risk of melioidosis is high in India owing to its agrarian economy. Exposure to muddy water increases the likelihood of skin inoculation, making the condition more prevalent during the rainy season. In the present case, the patient's heavy alcohol use and undiagnosed diabetes were significant risk factors. While his occupation as a businessman did not inherently pose a high risk, it was possible for him to be exposed to *B. pseudomallei* through skin inoculation. The manifestations occurred during the rainy season in this case. Considering the progression of the disease in this patient, it is plausible that the pneumonia resulted from haematogenous spread from the inoculation site.

Colonies of *B. pseudomallei* generally appear wrinkled and are often mistaken for environmental contaminants or aerobic spore-forming bacilli, leading to their inadvertent discarding.^[10] Precise identification using conventional microbiological techniques is extremely challenging, even when the genus is correctly identified. Many centres in India,

particularly in government settings, still rely solely on conventional microbiological methods for diagnosis. Incorporating automated methods such as VITEK 2 Compact and MALDI-TOF in these sectors would expedite and improve the diagnosis of infectious diseases. In cases of melioidosis, the need for faster identification cannot be emphasised enough. A combination of tests increases the diagnostic sensitivity and accuracy. In the described case, the blood culture was positive for *B. pseudomallei*, which was strong evidence to start treatment without delay. Rapid identification and accurate aggressive treatment helped in patient recovery. This infection was acquired in the community, before hospital admission, through skin inoculation, subsequently affecting the respiratory system. However, the exact source of the pathogen in this case could not be determined from the patient's history.

B. pseudomallei is intrinsically resistant to the penicillin group of drugs, 1st and 2nd generation cephalosporins and gentamicin. It is prudent to select antibiotics after obtaining the antibiotic susceptibility report. Piperacillin, amoxicillin-clavulanate, ceftazidime and carbapenems are effective drugs. Trimethoprim-sulfamethoxazole, because of its high tissue penetration, is also a reliable drug especially in this case with cutaneous and bone-joint melioidosis. In the present case, the patient was initially started with intravenous drugs intensively for 2 weeks and then prescribed oral antibiotics (i.e., cotrimoxazole) for an extended period of 6 months because of osteoarticular involvement.^[3] The patient is presently fully recovered and doing well.

Conclusion

Maintaining good communication between treating physicians and microbiologists is crucial to avoid any delays in pathogen identification. Furthermore, proper interpretation of the identification methods is paramount for confirming causative organisms. Using a combination of methods increases the confidence of identification. Microbiologists and doctors who are less knowledgeable about the clinical condition are also more likely to miss the diagnosis and use the wrong drugs. Early diagnosis and appropriate treatment are essential in cases of melioidosis to prevent fatality. A high level of suspicion, awareness and a prompt approach to diagnosis and treatment are vital for saving lives.

Declaration. Written consent and permission were obtained from the patient for the use of the patient's information and images.

Acknowledgements. Department of Microbiology and Critical Care Medicine, SGPGI, Lucknow, India.

Author contributions. ST wrote the initial draft of the manuscript. SP and SG critically reviewed and edited the manuscript.

Funding. None.

Data availability statement. Data cannot be made available since these are extracted from medical records of a patient.

Conflicts of interest. None.

CASE REPORT

1. Mukhopadhyay C, Eshwara VK, Hattangadi VB. Melioidosis. *J Acad Clin Microbiol* 2013;15(1):11-18.
2. Limmathurotsakul D, Chaowagul W, Chierakul W, et al. Risk factors for recurrent melioidosis in Northeast Thailand. *Clin Infect Dis* 2006 Oct 15;43(8):979-986. <https://doi.org/10.1086/507632>
3. Pitman MC, Luck T, Marshall CS, Anstey NM, Ward L, Currie BJ. Intravenous therapy duration and outcomes in melioidosis: A new treatment paradigm. *PLoS Negl Trop Dis* 2015;26;9(3):e0003586. <https://doi.org/10.1371/journal.pntd.0003586>
4. Birnie E, Virk HS, Savelkoel J, et al. Global burden of melioidosis in 2015: A systematic review and data synthesis. *Lancet Infect Dis* 2019;19(8):892-902. [https://doi.org/10.1016/S1473-3099\(19\)30157-4](https://doi.org/10.1016/S1473-3099(19)30157-4)
5. Liu L, Gee J, Blaney D. Melioidosis: CDC Yellow Book 2024. <https://wwwnc.cdc.gov/travel/yellowbook/2024/infections-diseases/melioidosis> (accessed 27 June 2023).
6. Chowdhury S, Barai L, Afroze SR, et al. The epidemiology of melioidosis and its association with diabetes mellitus: A systematic review and meta-analysis. *Pathogens* 2022;11(2):149. <https://doi.org/10.3390/pathogens11020149>
7. Achappa B, Madi D, Vidyalakshmi K. Cutaneous melioidosis. *J Clin Diagn Res* 2016 Sep;10(9):WD01-2.
8. Currie BJ, Ward L, Cheng AC. The epidemiology and clinical spectrum of melioidosis: 540 cases from the 20 year Darwin prospective study. *PLoS Negl Trop Dis* 2010;4(11):e900. <https://doi.org/10.1371/journal.pntd.0000900>
9. Fertitta L, Monsel G, Torresi J, Caumes E. Cutaneous melioidosis: A review of the literature. *Int J Dermatol* 2019;58(2):221-227. <https://doi.org/10.1111/ijd.14167>
10. Mohapatra PR, Mishra B. Burden of melioidosis in India and South Asia: Challenges and ways forward. *Lancet Reg Health - Southeast Asia*. 2022 July 1. [https://www.thelancet.com/journals/lansea/article/PIIS2772-3682\(22\)00004-X/fulltext](https://www.thelancet.com/journals/lansea/article/PIIS2772-3682(22)00004-X/fulltext) (accessed 21 June 2023).

Received 6 August 2023. Accepted 5 June 2024.