

GUEST EDITORIAL

# Cystic echinococcosis: The parasitic tale of a sinister cystic disease

Cystic echinococcosis (CE) is a zoonotic disease caused by the parasitic tapeworm *Echinococcus granulosus sensu lato*. It is endemic in South America, China, Turkey, India, Australia, and Middle and Eastern European countries, with prevalence rates of up to 10% in endemic populations.<sup>[1-6]</sup> In Africa, the reported prevalence of CE is as low as 1.7%, a figure that grossly underestimates the disease burden.<sup>[7]</sup> Similarly, there is a paucity of epidemiological data for South Africa (SA). Although Wahlers *et al.*<sup>[8]</sup> conservatively estimated ~135 - 140 new cases of CE annually in SA, the same authors raised concerns after analysing data from the National Health Laboratory Service suggesting that annual numbers are steadily increasing. Since CE mainly affects the poorer and more disadvantaged population, cases are likely to be underdiagnosed and underreported, and the development of new drugs and other treatment modalities is slow.<sup>[9,10]</sup>

Owing to its direct effects on organ or carcass condemnation and indirect effects on human and animal health, CE has a substantial negative economic impact.<sup>[9-11]</sup> Humans, who serve as accidental hosts (Fig. 1), become infected through the inadvertent ingestion of soil, water or food that has been contaminated by the excrement of an afflicted dog.<sup>[1,6,12]</sup> Soil-deposited echinococcus eggs can remain viable for a duration of 1 year.<sup>[13]</sup> Once the parasite is consumed, it migrates from the intestine through the portal venous system to the liver and subsequently to the lungs. Although the most common sites of disease are the liver (70%) and lungs (20%), the disease may manifest in any organ.<sup>[1,3,6]</sup> Signs and symptoms are largely nonspecific, especially in the early stage of the disease; patients therefore often present late when the large cyst has some mechanical and compressive effects on organ function, or when rupture of a cyst causes acute hypersensitivity reactions.<sup>[1,3,6]</sup> Although hydatid cysts typically grow slowly, authors have reported accelerated cystic growth in patients with immunosuppressive states, which is relevant in our setting given the ongoing HIV and tuberculosis epidemics in sub-Saharan Africa.<sup>[12,14]</sup>

CE is currently on the list of neglected tropical diseases that the World Health Organization aims to eradicate or control by the year 2030,<sup>[5,6,15,16]</sup> and in theory, it is

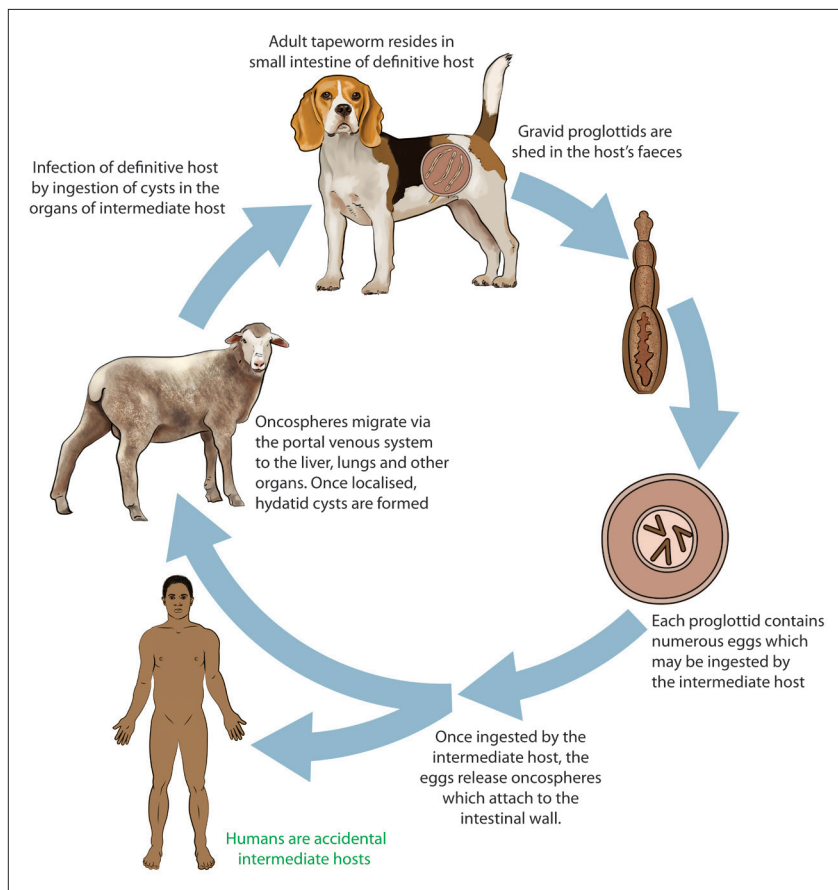


Fig. 1. Schematic diagram showing the life cycle of *Echinococcus granulosus sensu lato* (figure reproduced from Govindasamy *et al.*,<sup>[6]</sup> with permission).

preventable, eliminable and treatable.<sup>[1,5]</sup> To this end, development of health education and promotion activities in the community, orientated towards disease control, is essential to bring about changes in the behaviour of humans, especially children.<sup>[13]</sup> The biological cycle can also be struck at various points, as has been observed in many parts of the world. The initiation of dog deworming programmes and ensuring strict, safe sheep slaughtering practices have resulted in a major decline in numbers in Tasmania and New Zealand.<sup>[1,6,13]</sup> Similarly, Argentina, Chile and Uruguay saw a similar reduction in CE with dog deworming programmes.<sup>[3,6,11,13]</sup> The programmes utilised supervised dog deworming with praziquantel at intervals between four and eight times annually.<sup>[6,13]</sup> Vaccination of sheep with the EG95 vaccine has assisted in transmission reduction in China and Argentina; however, the high cost

of the vaccine prevents its use in low-income countries where CE is endemic.<sup>[6,13]</sup> Attempts at dog vaccination have been described, but this has not shown proven measurable outcomes in CE transmission reduction.<sup>[6,12,13]</sup> These strategies require long-lasting efforts. To enable clinicians and health authorities to plan informed strategies, it is the responsibility of clinicians across various specialties to expand local epidemiological data and further unmask the true burden of this disease. In this month's CME, we present a study that examined the demographic and clinical profiles of patients with liver CE at a single tertiary hospital in Eastern Cape Province, SA.<sup>[17]</sup> This study reports the largest number of liver CE cases managed in a single centre in SA to date. It also provides a glimpse of the burden of liver CE disease, where we are merely observing the tail end of this sinister parasitic infection.


**Jeff John** 

*Division of Urology, Department of Surgery, Frere Hospital and Faculty of Medicine and Health Sciences, Walter Sisulu University, East London, South Africa; Division of Urology, Department of Surgery, Faculty of Health Sciences, University of Cape Town, South Africa*  
 Guest Editor  
[jeffveenajohn@gmail.com](mailto:jeffveenajohn@gmail.com)

- Bhutani N, Kajal P. Hepatic echinococcosis: A review. *Ann Med Surg (Lond)* 2018;36:99-105. <https://doi.org/10.1016/j.amsu.2018.10.032>
- Mönnink GLE, Stijns C, van Delden OM, Spijker R, Grobusch MP. Percutaneous versus surgical interventions for hepatic cystic echinococcosis: A systematic review and meta-analysis. *Cardiovasc Intervent Radiol* 2021;44(11):1689-1696. <https://doi.org/10.1007/s00270-021-02911-4>
- Tsoufas G, Hoballah JJ, Velmahos GC, Ho Y-K. *The Surgical Management of Parasitic Diseases*. Cham, Switzerland: Springer, 2020.
- Wahlers K, Menezes CN, Wong ML, et al. Cystic echinococcosis in sub-Saharan Africa. *Lancet Infect Dis* 2012;12(11):871-880. [https://doi.org/10.1016/S1473-3099\(12\)70155-X](https://doi.org/10.1016/S1473-3099(12)70155-X)
- Tamarozzi F, Akhan O, Cretu CM, et al. Prevalence of abdominal cystic echinococcosis in rural Bulgaria, Romania, and Turkey: A cross-sectional, ultrasound-based, population study from the HERACLES project. *Lancet Infect Dis* 2018;18(7):769-778. [https://doi.org/10.1016/S1473-3099\(18\)30221-4](https://doi.org/10.1016/S1473-3099(18)30221-4)
- Govindasamy A, Bhattarai PR, John J. Liver cystic echinococcosis: A parasitic review. *Ther Adv Infect Dis* 2023;10:20499361231171478. <https://doi.org/10.1177/20499361231171478>
- Karshima SN, Ahmed MI, Adamu NB, Magaji AA, Zakariah M, Mohammed K. Africa-wide meta-analysis on the prevalence and distribution of human cystic echinococcosis and canine *Echinococcus granulosus* infections. *Parasit Vectors* 2022;15(1):357. <https://doi.org/10.1186/s13071-022-05474-6>
- Wahlers K, Menezes CN, Wong M, et al. Human cystic echinococcosis in South Africa. *Acta Trop* 2011;120(3):179-184. <https://doi.org/10.1016/j.actatropica.2011.08.006>
- Budke CM, Deplazes P, Torgerson PR. Global socioeconomic impact of cystic echinococcosis. *Emerg Infect Dis* 2006;12(2):296-303. <https://doi.org/10.3201/eid1202.050499>
- Budke CM, Carabin H, Ndimubanzi PC, et al. A systematic review of the literature on cystic echinococcosis frequency worldwide and its associated clinical manifestations. *Am J Trop Med Hyg* 2013;88(6):1011-1027. <https://doi.org/10.4269/ajtmh.12-0692>
- Kern P, Menezes da Silva A, Akhan O, et al. The echinococcoses: Diagnosis, clinical management and burden of disease. *Adv Parasitol* 2017;96:259-369. <https://doi.org/10.1016/bs.apar.2016.09.006>
- Wen H, Vuitton L, Tuxun T, et al. Echinococcosis: Advances in the 21st century. *Clin Microbiol Rev* 2019;32(2):e00075-18. <https://doi.org/10.1128/CMR.00075-18>
- Craig PS, Hegglin D, Lightowlers MW, Torgerson PR, Wang Q. Echinococcosis: Control and prevention. *Adv Parasitol* 2017;96:55-158. <https://doi.org/10.1016/bs.apar.2016.09.002>
- Wahlers K, Menezes CN, Romig T, Kern P, Grobusch MP. Cystic echinococcosis in South Africa: The worst yet to come? *Acta Trop* 2013;128(1):1-6. <https://doi.org/10.1016/j.actatropica.2013.06.002>
- Craig PS, Budke CM, Schantz PM, et al. Human echinococcosis: A neglected disease? *Trop Med Health* 2007;35(4):283-292. <https://doi.org/10.2149/tmh.35.283>
- Casulli A. New global targets for NTDs in the WHO roadmap 2021-2030. *PLoS Negl Trop Dis* 2021;15(5):e0009373. <https://doi.org/10.1371/journal.pntd.0009373>
- Govindasamy A, Bhattarai PR, van Niekerk J, John J. Liver cystic echinococcosis: A retrospective study on the demographics and clinical profile of patients managed at a single tertiary institution in central Eastern Cape Province, South Africa. *S Afr Med J* 2024;114(5):e2195. <https://doi.org/10.7196/SAMJ.2024.v114i5.2195>

*S Afr Med J* 2024;114(5):e2193. <https://doi.org/10.7196/SAMJ.2024.v114i5.2193>