

Liver cystic echinococcosis: A retrospective study on the demographics and clinical profile of patients managed at a single tertiary institution in central Eastern Cape Province, South Africa

A Govindasamy,¹ MB ChB ; P R Bhattarai,¹ MBBS, MS (Gen Surg); J van Niekerk,² MB ChB, MSc; J John,^{3,4} FC Urol (SA), MMed

¹ Department of Surgery, Frere Hospital and Faculty of Health Sciences, Walter Sisulu University, East London, South Africa

² Department of Surgery, Cecilia Makiwane Hospital, East London, South Africa

³ Division of Urology, Department of Surgery, Frere Hospital and Faculty of Health Sciences, Walter Sisulu University, East London, South Africa

⁴ Division of Urology, Department of Surgery, University of Cape Town, South Africa

Corresponding author: A Govindasamy (avaan.govindasamy@gmail.com)

Background. Cystic echinococcosis (CE) is a zoonotic disease with an Africa-wide prevalence of 1.7%. CE is caused by the tapeworm *Echinococcus granulosus sensu lato*, with the liver being the most commonly affected organ. In South Africa (SA), there is a paucity of data on liver CE demographics and management.

Objectives. To describe the demographics and clinical profile of patients with liver CE in a single tertiary hospital in Eastern Cape Province, SA.

Methods. A 4-year (2019 - 2022) retrospective clinical record review study was conducted on patients presenting with liver CE to the Department of Surgery at Frere Hospital. The demographics, clinical characteristics and management of patients with liver CE are reported.

Results. A total of 56 patients diagnosed with and managed for liver CE were included in the study. The mean age of the patients was 37.5 years. Abdominal pain ($n=39$; 69.6%) was the most common presenting symptom, and a palpable abdominal mass ($n=36$; 64.3%) was the predominant presenting sign. Most patients had disease confined to the liver ($n=35$; 62.5%). The right lobe of the liver was most commonly affected ($n=38$; 67.9%), and most patients had a single liver cyst on imaging ($n=32$; 57.1%). The majority of the patients ($n=36$; 64.3%) were managed with surgical partial cystectomy, with a perioperative bile leak being the most common complication.

Conclusion. In our setting, liver CE contributes to a significant local burden of the disease. The disease often has a nonspecific clinical presentation, necessitating imaging for the diagnosis. We observed good short-term outcomes in patients managed with combined partial cystectomy and medical therapy, although there is a risk of perioperative bile leak.

S Afr Med J 2024;114(5):e2195. <https://doi.org/10.7196/SAMJ.2024.v114i5.2195>

Hydatid disease, also known as cystic echinococcosis (CE), is a parasitic zoonotic infection caused by the tapeworm *Echinococcus granulosus sensu lato*. Dogs are the definitive hosts and humans the accidental hosts in the parasite life cycle. CE occurs worldwide and is endemic in China, India, Australia, Turkey, and Middle Eastern, South American and Eastern European countries, where the prevalence can reach 10%.^[1-5] There are an estimated 2 - 3 million cases; however, owing to a paucity of epidemiological studies, it is believed that prevalence rates are grossly underestimated in endemic areas.^[6-9] The World Health Organization has aimed to eliminate this disease by 2030.^[6,10,11] In South Africa (SA), there is a paucity of epidemiological data on CE, specifically CE of the liver, which is the most commonly affected organ.^[11-13] In 2011, Wahlers *et al.*^[12] conservatively estimated the burden of human CE infection in SA to be ~137 cases per year in eight of the nine provinces (KwaZulu-Natal was excluded). The present study aimed to describe the demographic and clinical profiles of patients with liver CE at a single tertiary hospital in Eastern Cape Province, SA.

Methods

Design, setting and population

We retrospectively reviewed the records of all patients with liver CE who presented to the Department of Surgery at Frere Hospital between January 2019 and December 2022. The Department

provides tertiary services and all after-hours surgical management to the central region of Eastern Cape Province. This region encompasses four districts: the Buffalo City Metropolitan Municipality, Amathole Municipality, Chris Hani Municipality, and Joe Gqabi Municipality. It had a combined population of 3 068 291 in 2022.^[14]

Inclusion criteria

All patients aged ≥ 12 years who were diagnosed with liver CE based on radiological imaging of the liver using ultrasonography and/or computed tomography (CT) were included.

Statistical analysis

Data were captured on Excel 2019 (Microsoft Corp., USA). An Excel spreadsheet was used to evaluate variables including demographics (age, sex and location), presenting symptoms and signs, hydatid serological findings, liver imaging findings, management approaches and perioperative outcomes. Statistical analysis was carried out using Stata 2017 (StataCorp, USA). Statistical significance was set at $p < 0.05$. A 95% confidence interval was used. Descriptive statistics were used for data analysis. For numerical data, central tendency and variability are described using means and standard deviations (SDs) if normally distributed and medians and interquartile ranges (IQRs) if not normally distributed. The results are presented in

tables and graphs. We performed a *post hoc* analysis between bile leak and maximum mean cyst size, and bile leak and postoperative length of stay.

Ethical considerations

Ethical clearance (ref. no. 014/2023) was granted by the Walter Sisulu University (WSU) Faculty of Health Sciences Research Ethics and Biosafety Committee. Approval was obtained from the Eastern Cape Health Research Committee and Frere Hospital.

Results

Over the 4-year period 1 January 2019 - 31 December 2022, a total of 56 individuals received treatment for hepatic CE. There was a predominance of females (58.9%), with males comprising 41.1%. The mean (SD) age of the patients was 37.5 (20.03) years, with the youngest patient aged 12 years and the oldest 79 years. Amathole district accounted for the largest proportion of patients (62.5%), followed by Buffalo City (23.2%) and Chris Hani district (14.3%) (Fig. 1).

The presenting complaints included abdominal pain (69.6%), abdominal distension (48.2%) and both abdominal pain and distension (32.1%). A minority of patients experienced respiratory symptoms, including cough (10.7%), haemoptysis (1.8%) and dyspnoea (1.8%). All patients with respiratory symptoms had concomitant liver and pulmonary CE. Only two cases (3.6%) were asymptomatic, with the diagnosis based on incidental imaging findings. In patients who presented with clinical signs, a palpable abdominal mass (64.3%), abdominal tenderness (12.5%), jaundice (5.4%), peritonism (3.6%) and ascites (1.8%) were the most commonly documented findings on examination. Notably, almost a quarter of the patients (23.2%) had no abdominal signs on presentation.

Echinococcosis serology revealed that half (50%) of the patients had positive serological test results for CE, with an equal distribution of enzyme-linked immunosorbent assay (ELISA) and indirect hemagglutination test (IHA) tests. A negative result was observed in 12 patients (21.4%) with confirmed liver CE on imaging. In 16 cases (28.6%), neither test was recorded or available.

The radiological features identified on abdominal ultrasound, computed tomography or both are shown in Table 1. Of note, the right liver lobe (67.9%) was more commonly affected than the left lobe. The cysts ranged in size from 4 cm to 30 cm in largest diameter. The majority of patients had either a single liver cyst (57.1%) or two liver cysts (25.0%). Classification of the cyst stage of activity according to the World Health Organization Informal

Working Group on Echinococcosis (WHO-IWGE) showed that more than half of the cases were in the active stage of the disease (CE1). Most patients had isolated liver involvement (62.5%). The lungs (chest) were the second most affected site (19.6%), followed by intraperitoneal (8.9%) and splenic (8.9%) involvement. Less common sites were the pelvis, adnexa and omentum.

The majority of the patients were managed surgically with neoadjuvant and adjuvant albendazole cover, with open partial cystectomy being preferred (64.3%). Most cases were uneventful (54.1%). Documented complications in the remaining cases were perioperative surgical site infections (5.4%), and a single case of iatrogenic pleural breach (2.7%) during partial cystectomy. Perioperative bile leak was the most common complication in the surgically managed patients ($n=14$, 37.8%).

Table 1. Radiological characteristics of patients with cystic echinococcosis (N=56)

	<i>n</i> (%)
Imaging	
Ultrasound only	4 (7.1)
CT only	9 (16.1)
Both	43 (76.8)
Liver lobe affected	
Left	7 (12.5)
Right	38 (67.9)
Both	11 (19.6)
Number of cysts	
1	32 (57.1)
2	14 (25.0)
3	3 (5.4)
4	2 (3.6)
≥5	5 (8.9)
Size of largest cyst (cm)	
≤5	2 (3.6)
6 - 10	21 (37.5)
11 - 15	20 (35.7)
16 - 20	7 (12.5)
>20	6 (10.7)
WHO-IWGE classification	
CE1	32 (57.1)
CE2	6 (10.7)
CE3a	10 (17.9)
CE3b	5 (8.9)
CE4	3 (5.4)
CE5	0
Other organs involved	
Liver + chest	11 (19.6)
Liver + intraperitoneal	5 (8.9)
Liver + spleen	5 (8.9)
Liver + pelvis	3 (5.4)
Liver + adnexa	2 (3.6)
Liver + omentum	1 (1.8)
Number of additional organ systems involved	
None (liver only)	35 (62.5)
1	15 (26.8)
2	5 (8.9)
4	1 (1.8)

CT = computed tomography; WHO-IWGE = World Health Organization Informal Working Group on Echinococcosis.

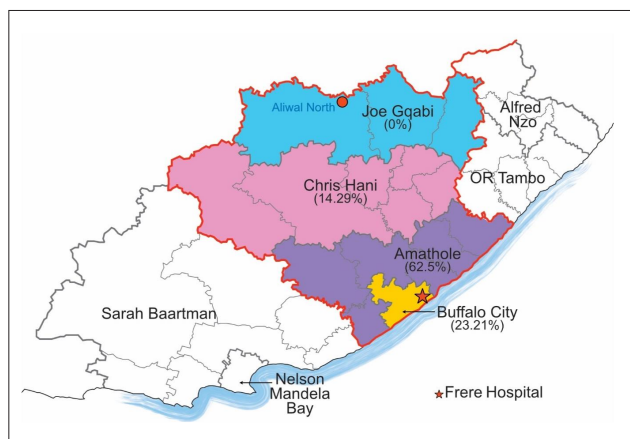


Fig. 1. Geographical distribution of liver cystic echinococcosis across different districts in central Eastern Cape Province.

Only one patient underwent puncture, aspiration, injection and re-aspiration (PAIR) standard catheterisation (1.8%). Just over a third of the patients were treated with medical therapy alone (Fig. 2).

The median postoperative length of stay was 7 days, and there were no perioperative deaths, with 100% survival to discharge. On bivariate analysis, we observed no statistically significant difference in mean maximum cyst size between patients with and without a perioperative bile leak (Table 2).

We observed a statistically significant difference in mean postoperative length of stay between patients who sustained a bile leak and those who did not. On average, patients with a bile leak had 9.83 days longer postoperative length of stay (Table 3).

Discussion

CE is a zoonotic disease frequently observed in regions where dogs and sheep-raising activities interact closely.^[15] A recent Africa-wide meta-analysis on the prevalence and distribution of CE showed a modest prevalence of 1.7% on the continent.^[11,16] Liver CE is the commonest manifestation of the disease, and it is underdiagnosed and poorly studied in SA.^[12]

The present study retrospectively analysed the demographic and clinical features of 56 patients diagnosed with hepatic CE. The mean age of the patients was 37.5 years, and there was a preponderance of females. The traditional role of women in rural regions means that they are typically responsible for household duties, thereby increasing their exposure to potential sources of tapeworm eggs such as dogs, polluted water, soil and vegetables, and makes females more vulnerable than males.^[17-22] CE can affect individuals of all age groups, but patients typically experience symptoms and indicators of the disease at a relatively late stage,^[3,18] because the cysts in the liver grow slowly (at a rate of 1 - 5 mm per year).^[3,18]

In terms of geographical location, the majority of our patients lived in Amathole district. The towns Kentani, Idutywa, Nqamakwe and Butterworth, which are located in this district, collectively represented >50% of the total cases in this study. This district is regarded as one of the most economically disadvantaged places in SA, accounting for approximately a quarter (26.2%) of the poverty gap in the Eastern Cape, and the majority of households (68.5%) have an income that falls below the poverty line.^[23-25] People living in rural areas face elevated susceptibility to transmission of CE, primarily as a result of increased exposure to sources carrying the infection. The risk of exposure to infected parasite eggs is increased by factors such as rural livestock, slaughtering practices and unsafe offal disposal. Dogs feeding on infected offal in the vicinity further perpetuate the life cycle and transmission of the parasite to the environment.^[20,21] Similarly, Ngcobo *et al.*^[26] noted that the majority

of pulmonary CE cases in their study were from rural areas of KwaZulu-Natal and Eastern Cape provinces.

The majority of our patients (62.5%) had solitary liver CE. The lungs, spleen and peritoneum were the organs most frequently affected when multiple organs were involved. The most prevalent symptom and sign of hepatic CE were abdominal pain and a palpable abdominal mass, consistent with reports by other authors.^[15,22,27-29] Some authors have reported that symptoms occur when the cyst is large (>10 cm) or when it occupies >70% of the liver volume.^[1,2,6,29,30] However, in our study, 12 patients with cysts measuring between 7 and 9 cm also reported abdominal symptoms.

Complicated presentations of liver CE include jaundice resulting from biliary obstruction or cystic compression, ascites, respiratory symptoms caused by a cystopleural fistula, and severe allergic reactions or anaphylactic shock resulting from rupture of the cyst into the peritoneal cavity.^[1,3,31] In our study, three patients presented with jaundice. Two patients had large cysts causing compression of the intrahepatic biliary ductal system. Both patients underwent partial cystectomy, with a cystobiliary fistula noted intraoperatively. Another patient had inoperable, disseminated intraperitoneal disease with common bile duct compression noted on CT imaging. Endoscopic retrograde cholangiopancreatography (ERCP), sphincterotomy and stenting were performed to resolve the biliary obstruction.

Peritonism was noted in two patients, both of whom had ruptured liver cysts. Interestingly, no anaphylactic reactions were observed in either of these patients. Both patients with peritonism underwent medical-only therapy, as one patient refused surgery and the

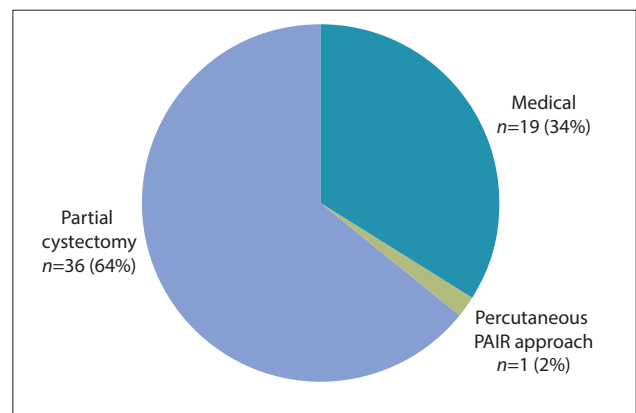


Fig. 2. Management of patients with liver cystic echinococcosis at Frere Hospital, Eastern Cape Province (N=56). (PAIR = puncture, aspiration, injection and re-aspiration.)

Table 2. Bivariate analysis of bile leak and maximum cyst size

Maximum cyst size (cm)	Bile leak (N=37)		t-score (p-value)
	0 - No (n=23)	1 - Yes (n=14)	
Mean (SD)	13.65 (5.32)	13.93 (6.195)	-0.1440 (0.8863)
Median (IQR)	13 (10 - 16)	11.5 (9.75 - 17.25)	

SD = standard deviation; IQR = interquartile range.

Table 3. Bivariate analysis of postoperative length of stay and bile leak

Length of stay (days)	Bile leak (N=37)		t-score (p-value)
	0 - No (n=23)	1 - Yes (n=14)	
Mean (SD)	5.96 (1.46)	15.79 (10.07)	-4.7465 (0.000)
Median (IQR)	5 (5 - 8)	16.5 (7 - 20.25)	

SD = standard deviation; IQR = interquartile range.

other was deemed inoperable. On follow-up imaging, neither patient had features of secondary hydatidosis, with degenerative changes of the ruptured liver cyst seen on follow-up imaging. Ascites was seen in one complicated case of a patient with three liver cysts and disseminated intraperitoneal disease causing adjacent intra-abdominal organ compression requiring surgical cystic debulking.

Serological tests, using ELISA, IHA and Western blot, only play a minor confirmatory role in the investigation of liver CE and are not consistently performed.^[19,28,32,33] In the present study, clinicians did not perform serological tests in just over a quarter of the patients (28.6%). These tests are typically performed when imaging findings are equivocal.^[6,9,29,34-37] A proportion of our patients had a negative result (21.4%) despite the findings on imaging being consistent with the diagnosis of liver CE. A seronegative result may occur due to the encapsulation of early cyst antigens by the endocyst, which prevents their detection by the immune system. Another possible reason is calcification of the cyst walls, which is observed in more advanced stages of cyst development.^[3]

Imaging findings indicated that the right liver lobe was most commonly affected, accounting for two-thirds of the cases in this study, correlating with a larger retrospective review study of 227 patients in Greece.^[38] The preferential blood flow to the right lobe via the portal vein predisposes the right lobe to disease.^[15,27] A single cyst was seen in the liver in just over half of the cases, with the majority of the cysts between 6 cm and 10 cm in maximum diameter, which is consistent with other reports.^[18,22,29,32,39,40] A remarkable proportion (58.9%) of patients presented with large cysts, defined as those with a maximum diameter of >10 cm.^[28] This finding may indicate that patients delay seeking medical attention and present only when the disease has advanced.

The WHO-IGWE categorises liver CE cysts into several stages, as shown in Fig. 3. CE1 and CE2 cysts are associated with active disease stages. CE3a and CE3b represent transitional stages, while CE4 and CE5 correspond to an inactive cyst. This classification also provides further guidelines for managing the cyst based on its stage.^[6,30,34,39] In our study, the majority of cysts were in the active stage, with just over half of all cases classified as CE1. This finding aligns with previous reports that CE1 is the stage most often observed on imaging.^[20,21,28]

Owing to the blood supply of the portal venous system, the liver is the primary

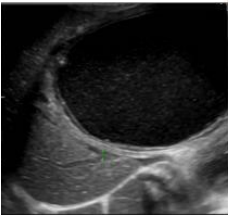






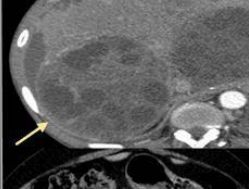


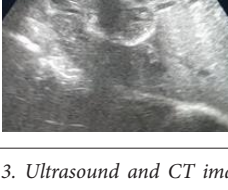
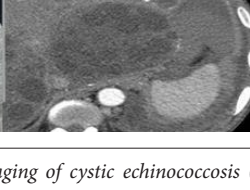
Ultrasound imaging WHO-IGWE	CT imaging	Classification	Stage
		CE1 Unilocular anechoic cyst	Active
		CE2 Multiple septations	Active
		CE3a Detached membrane	Transitional
		CE3b Daughter cysts in solid matrix	Transitional
		CE4 Hypoechoic and hyperechoic contents in cyst	Inactive
		CE5 Calcified cystic wall	Inactive

Fig. 3. Ultrasound and CT imaging of cystic echinococcosis (figure reproduced from Govindasamy et al.,^[6] with permission). (CT = computed tomography; WHO-IGWE = World Health Organization Informal Working Group on Echinococcosis.)

site affected by CE (~70% of cases), followed by the lungs and spleen.^[1,15,26,29,39-41]

In the present study, the majority of patients (62.5%) had isolated liver involvement. It is worth mentioning that none of the patients with intraperitoneal involvement had previously undergone abdominal surgery for hydatid disease. Intraperitoneal CE is believed to result from either primary intraperitoneal disease (rare) or secondary hydatidosis from a previous cystic rupture.^[42] In our study, peritoneal cysts were considered secondary cysts due to dissemination. Pelvic CE refers to abdominal CE found adjacent to the bladder and rectum.^[40,43] The

single case of CE of the omentum could in theory be categorised as part of the intraperitoneal group. However, a single cyst in the omentum was found in this case, with no other intraperitoneal cysts, and it was therefore reported as a single case entity. Our finding of a single omental cyst correlates with a larger retrospective study that reported a small number of cases with isolated omental involvement.^[40]

Patient management included albendazole monotherapy, routine percutaneous catheterisation (PAIR), and open partial cystectomy. Albendazole monotherapy was reserved for patients with small (<5 cm) CE1 and CE3a liver

cysts,^[1,6,41] those who were considered unfit for surgical intervention, those who had multiple cysts in more than two organs, or those who had peritoneal cysts.^[1,5,6] All patients who underwent percutaneous and partial cystectomy received preoperative and postoperative albendazole cover. Seven patients (12.5%) in this study refused or defaulted from surgery, leaving them with albendazole monotherapy for hepatic CE.

The percutaneous ultrasound-guided approach for the treatment of liver CE entails injecting a scolicidal chemical to sterilise the cystic contents (Fig. 4). The PAIR technique is the most frequently employed method, specifically recommended for CE1 and CE3a single-compartment cysts measuring <10 cm. In patients with a cystobiliary fistula or CE2 or CE3b cysts, or where no safe ultrasound guidance is available, the PAIR technique should be avoided.^[1,5,6,41] Our unit does not have an interventional radiologist for intraoperative real-time imaging during percutaneous drainage, and for this reason, this technique was only used in one patient. This patient presented with predominantly respiratory complaints after a cystobiliary fistula had eroded and ruptured through the diaphragm into the pleural cavity, causing a pleural effusion. Emergency ultrasound-guided catheterisation and drainage of the liver cyst was performed. The liver cyst was easily accessible and had a diameter of 10 cm, making the procedure safe. The biliary fistula resolved with ERCP sphincterotomy and stent placement, with subsequent resolution of the bilious effusion after ERCP.

Surgical approaches (Fig. 4) can be conservative (partial cystectomy) or radical (total cystectomy or hepatectomy). Under perioperative albendazole cover, partial cystectomy involves deroofting part of the pericyst, after which the cystic contents are sterilised with a scolicidal agent and removed. Although partial cystectomy is technically safer and easier to perform compared with radical surgical approaches, it has an increased risk of recurrence, cystic cavity infection and cystobiliary fistula occurrence.^[1,3,36,41,44] Of our 56 patients managed for liver CE, 36 (64.3%) underwent open surgery with partial cystectomy.

More than half (54.1%) of the patients who underwent partial cystectomy had an uncomplicated postoperative course. As expected, the most common complication in the remaining patients was perioperative bile leak, correlating with a larger retrospective review study in India.^[45]

In the present study, the median (IQR) length of hospital stay was 7 (5 - 8) days. CE has a low mortality rate (2 - 4%), and

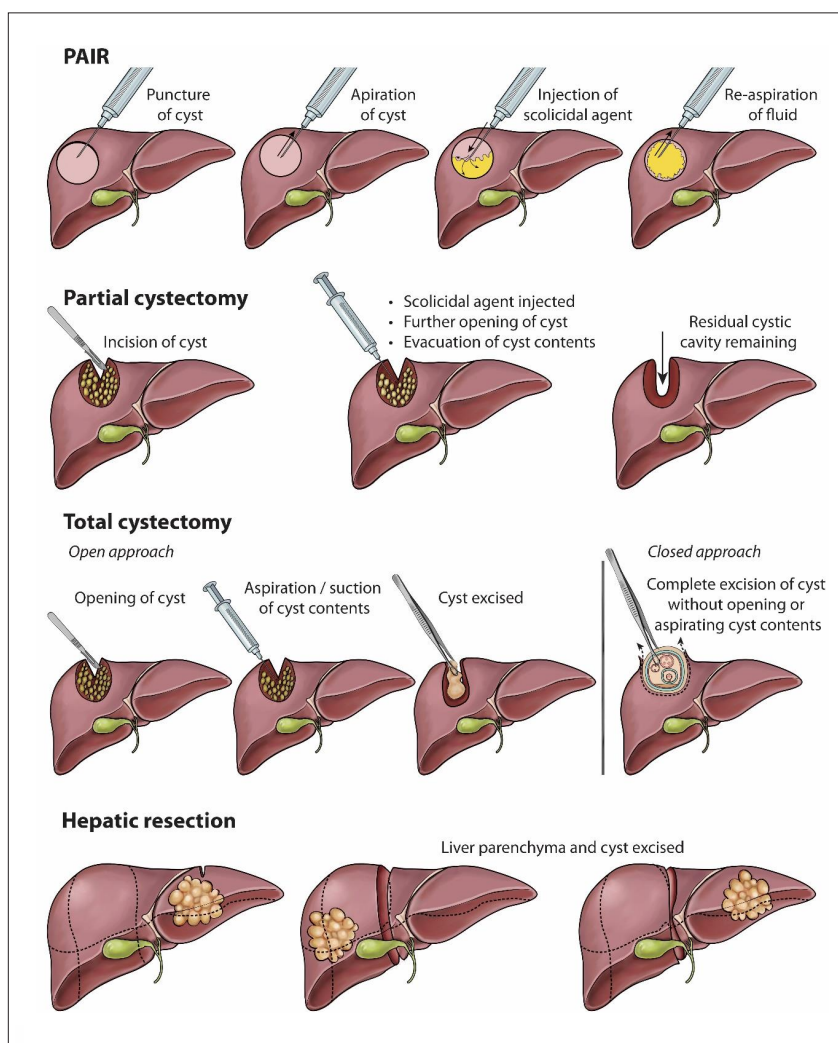


Fig. 4. Surgical management options for liver cystic echinococcosis (figure reproduced from Govindasamy *et al.*,^[6] with permission). (PAIR = puncture, aspiration, injection and re-aspiration.)

our study correlates with a study by Escolá-Vergé *et al.*^[32] reporting no CE-related deaths.

We acknowledge some limitations of our study. A retrospective record review study is inherently limited by the potential for poor record keeping. In addition, information regarding long-term outcomes after hospital discharge is unavailable. For this reason, it was not possible to determine recurrence rates. Secondly, our study was limited to a single tertiary facility in the province and only enrolled patients who were ≥ 12 years of age. Both these factors limit the sample size and external validity of the study findings.

Conclusion

The findings of this study demonstrate a significant number of liver CE cases in central Eastern Cape Province. The majority of patients presented with nonspecific abdominal symptoms,

suggesting that liver CE should be included in the differential diagnosis, especially in endemic areas. In addition, patients need to be timeously referred to appropriate facilities for further diagnostic work-up and treatment. Conservative surgical options such as partial cystectomy are more widely practised than radical approaches, because they are relatively safe and more straightforward to perform; however, they are associated with a higher risk of perioperative bile leak. It is necessary to develop public health initiatives targeting dog deworming programmes and safe slaughtering methods in rural regions in order to control the transmission of this preventable zoonotic illness.

Declaration. The research for this study was done in partial fulfilment of the requirements for AG's MMed (General Surgery) degree at Walter Sisulu University.

Acknowledgements. The authors thank E J K Simpson and the Department of Surgery, Frere Hospital, for ongoing support throughout the research process.

Author contributions. AG: conceptualisation; writing – original draft; writing – review and editing; methodology. PRB: formal analysis. JvN: data curation; validation. JJ: resources; supervision; visualisation; writing – review and editing; formal analysis.

Funding. None.

Conflicts of interest. None.

- Kern P, Menezes da Silva A, Akhan O, et al. The echinococcoses: Diagnosis, clinical management and burden of disease. *Adv Parasitol* 2017;96:259-369. <https://doi.org/10.1016/b.sapar.2016.09.006>
- Bhutani N, Kajari P. Hepatic echinococcosis: A review. *Ann Med Surg (Lond)* 2018;36:99-105. <https://doi.org/10.1016/j.amsu.2018.10.032>
- Tsoufas G, Hoballah JJ, Velmahos GC, Ho Y-K. The Surgical Management of Parasitic Diseases. Cham, Switzerland: Springer, 2020.
- Tamarozzi F, Akhan O, Cretu CM, et al. Prevalence of abdominal cystic echinococcosis in rural Bulgaria, Romania, and Turkey: A cross-sectional, ultrasound-based, population study from the HERACLES project. *Lancet Infect Dis* 2018;18(7):769-778. [https://doi.org/10.1016/S1473-3099\(18\)30221-4](https://doi.org/10.1016/S1473-3099(18)30221-4)
- Khuroo MS. Percutaneous drainage in hepatic hydatidosis – the PAIR technique: Concept, technique, and results. *J Clin Exp Hepatol* 2021;11(5):592-602. <https://doi.org/10.1016/j.jceh.2021.05.005>
- Govindasamy A, Bhattarai PR, John J. Liver cystic echinococcosis: A parasitic review. *Ther Adv Infect Dis* 2023;10:20499361231171478. <https://doi.org/10.1177/20499361231171478>
- Mönnink GLE, Stijns C, van Delden OM, Spijker R, Grobusch MP. Percutaneous versus surgical interventions for hepatic cystic echinococcosis: A systematic review and meta-analysis. *Cardiovasc Intervent Radiol* 2021;44(11):1689-1696. <https://doi.org/10.1007/s00270-021-02911-4>
- Dehkordi AB, Sanei B, Yousefi M, et al. Albendazole and treatment of hydatid cyst: Review of literature. *Infect Disord Drug Targets* 2019;19(2):101-104. <https://doi.org/10.2174/1871526518666180629134511>
- Fadel SA, Asmar K, Faraj W, Khalife M, Haddad M, El-Merhi F. Clinical review of liver hydatid disease and its unusual presentations in developing countries. *Abdom Radiol (NY)* 2019;44(4):1331-1339. <https://doi.org/10.1007/s00261-018-1794-7>
- Casulli A. New global targets for NTDs in the WHO roadmap 2021-2030. *PLoS Negl Trop Dis* 2021;15(5):e0009373. <https://doi.org/10.1371/journal.pntd.0009373>
- John J. Cystic echinococcosis: The parasitic tale of a sinister cystic disease. *S Afr Med J* 2024;114(5):eXXXX. <https://doi.org/10.7196/SAMJ.2024.v114i5.XXXX> (this issue).
- Wahlers K, Menezes CN, Wong M, et al. Human cystic echinococcosis in South Africa. *Acta Trop* 2011;120(3):179-184. <https://doi.org/10.1016/j.actatropica.2011.08.006>
- Mogoye BK, Menezes CN, Wong ML, et al. First insights into species and genotypes of *Echinococcus* in South Africa. *Vet Parasitol* 2013;196(3-4):427-432. <https://doi.org/10.1016/j.vetpar.2013.03.033>
- Statistics South Africa. Census 2022: Eastern Cape. <https://census.statssa.gov.za/#/province/2/2> (accessed 2 January 2024).
- Baruah A, Sarma K, Barman B, Phukan P, Nath C, Boruah P, et al. Clinical and laboratory presentation of hydatid disease: A study from northeast India. *Cureus* 2020;12(9):e10260. <https://doi.org/10.7759/cureus.10260>
- Karshima SN, Ahmed MI, Adamu NB, Magaji AA, Zakariah M, Mohammed K. Africa-wide meta-analysis on the prevalence and distribution of human cystic echinococcosis and canine *Echinococcus granulosus* infections. *Parasit Vectors* 2022;15(1):357. <https://doi.org/10.1186/s13071-022-05474-6>
- Parkoobi PI, Jahani M, Hosseinzadeh F, et al. Epidemiology and clinical features of hydatid cyst in northern Iran from 2005 to 2015. *Iran J Parasitol* 2018;13(2):310-316. <http://www.embase.com/search/results?subaction=viewrecord&from=export&id=L622794133> (accessed 4 January 2024).
- Shahriarirad R, Erfani A, Eskandarisani M, Rastegarian M, Taghizadeh H, Sarkari B. Human cystic echinococcosis in southwest Iran: A 15-year retrospective epidemiological study of hospitalized cases. *Trop Med Health* 2020;48:49. <https://doi.org/10.1186/s41182-020-00238-3>
- Botezatu C, Mastalier B, Patrascu T. Hepatic hydatid cyst – diagnose and treatment algorithm. *J Med Life* 2018;11(3):203-209. <https://doi.org/10.25122/jml-2018-0045>
- Dorjsuren T, Ganzorig S, Dagvasumberel M, et al. Prevalence and risk factors associated with human cystic echinococcosis in rural areas, Mongolia. *PLoS ONE* 2020;15(7):e0235399. <https://doi.org/10.1371/journal.pone.0235399>
- Acosta-Jamett G, Hernández FA, Castro N, et al. Prevalence rate and risk factors of human cystic echinococcosis: A cross-sectional, community-based, abdominal ultrasound study in rural and urban north-central Chile. *PLoS Negl Trop Dis* 2022;16(3):e0010280. <https://doi.org/10.1371/journal.pntd.0010280>
- Erfani A, Shahriarirad R, Eskandarisani M, Rastegarian M, Sarkari B. Management of liver hydatid cysts: A retrospective analysis of 293 surgical cases from southern Iran. *J Trop Med* 2023;2023:9998739. <https://doi.org/10.1155/2023/9998739>
- Khumalo P, Thakathi DR. Challenges faced by the Amathole District Municipality in implementing LED policy. *Adm Publica* 2012;20(4):47-63.
- McCann M. Annexure 5: District Profile Eastern Cape O.R. Tambo District Municipality (DC15). European Consultants Organisation, 2005. <https://www.ecsecc.org/documentrepository/informationcentre/030407135344.pdf> (accessed 20 January 2024).
- Department of Cooperative Governance and Traditional Affairs. District Development Model: Amathole District, Eastern Cape. 2020. <https://www.cogta.gov.za/index.php/docs/amathole-district/> (accessed 20 January 2024).
- Ngcobo K, Madansein R, Ndlovu M, Masekela R. Surgical management of pulmonary hydatid cysts in children in KwaZulu-Natal Province, South Africa. *Afr J Thorac Crit Care Med* 2020;26(3):81-86. <https://doi.org/10.7196/AJTCCM.2020.v26i3.108>
- Illuri HR, Souza CD, Dias EAI, Das PP. Hydatid disease: A 2 years retrospective study in a tertiary care center in South India. *Int Surg J* 2018;5(2):602. <https://doi.org/10.18203/2349-2902.isj20180361>
- Petrone L, Cuzzi G, Colace L, et al. Cystic echinococcosis in a single tertiary care center in Rome, Italy. *Biomed Res Int* 2013;2013:978146. <https://doi.org/10.1155/2013/978146>
- Rashid MM, Rabbi H, Ahmed AT, et al. Outcome of surgically treated 79 patients of hepatic hydatidosis: A single center tertiary care hospital experience in Bangladesh. *J Surg Sci* 2020;22(2):118-124. <https://doi.org/10.3329/jss.v22i2.44076>
- Wen H, Vuitton L, Tuxun T, et al. Echinococcosis: Advances in the 21st century. *Clin Microbiol Rev* 2019;32(2):e00075-18. <https://doi.org/10.1128/CMR.00075-18>
- Rinaldi F, Brunetti E, Neumayr A, Maestri M, Goblrish S, Tamarozzi F. Cystic echinococcosis of the liver: A primer for hepatologists. *World J Hepatol* 2014;6(5):293-305. <https://doi.org/10.4254/wjh.v6.i5.293>
- Escalá-Vergé L, Salvador F, Sánchez-Montalvá A, et al. Retrospective study of cystic echinococcosis in a recent cohort of a referral center for liver surgery. *J Gastrointest Surg* 2019;23(6):1148-1156. <https://doi.org/10.1007/s11605-018-3971-y>
- Butt A, Khan JA. Cystic echinococcosis: A 10-year experience from a middle-income country. *Trop Doct* 2020;50(2):117-121. <https://doi.org/10.1177/0049475519891338>
- Keong B, Wilkie B, Sutherland T, Fox A. Hepatic cystic echinococcosis in Australia: An update on diagnosis and management. *ANZ J Surg* 2018;88(1-2):26-31. <https://doi.org/10.1111/ans.14117>
- Stojković M, Weber TF, Junghans T. Clinical management of cystic echinococcosis: State of the art and perspectives. *Curr Opin Infect Dis* 2018;31(5):383-392. <https://doi.org/10.1097/QCO.0000000000000485>
- Mihmanli M, Tanal M, Bozkurt E, Guven O. The surgical management of hydatid cyst of the liver: What is new? In: Derbel F, Braiki M, eds. *Overview on Echinococcosis*. IntechOpen, 2020. <https://doi.org/10.5772/intechopen.90726>
- Tamarozzi F, Silva R, Fittipaldo VA, Buonfrate D, Gottstein B, Siles-Lucas M. Serology for the diagnosis of human hepatic cystic echinococcosis and its relation with cyst staging: A systematic review of the literature with meta-analysis. *PLoS Negl Trop Dis* 2021;15(4):e0009370. <https://doi.org/10.1371/journal.pntd.0009370>
- Symeonidis N, Pavlidis T, Baltatzis M, et al. Complicated liver echinococcosis: 30 years of experience from an endemic area. *Scand J Surg* 2013;102(3):171-177. <https://doi.org/10.1177/1457496913491877>
- Ahmadi NA, Hamidi M. A retrospective analysis of human cystic echinococcosis in Hamedan province, an endemic region of Iran. *Ann Trop Med Parasitol* 2008;102(7):603-609. <https://doi.org/10.1179/136485908X337517>
- Aydin Y, Ulas AB, Ince I, et al. Large case series analysis of cystic echinococcosis. *Indian J Surg* 2021;83(Suppl 4):897-906. <https://doi.org/10.1007/s12262-021-03061-0>
- Brunetti E, Kern P, Vuitton DA. Expert consensus for the diagnosis and treatment of cystic and alveolar echinococcosis in humans. *Acta Trop* 2010;114(1):1-16. <https://doi.org/10.1016/j.actatropica.2009.11.001>
- Kosmidis C, Efthimiadis C, Anthimidis G, et al. Management of peritoneal hydatid cysts: A forty-year experience. *Heliyon* 2018;4(12):e00994. <https://doi.org/10.1016/j.heliyon.2018.e00994>
- Vagholkar K, Pawanarkar A, Chougale Q, Vagholkar S. Surgery for intra-abdominal hydatid disease: A single centre experience. *Int J Res Med Sci* 2016;4(10):4241-4245. <https://doi.org/10.18203/2320-6012.ijrms20163106>
- Öztürk G, Uzun MA, Özkan ÖF, et al. Turkish HPB Surgery Association consensus report on hepatic cystic echinococcosis (HCE). *Turk J Surg* 2022;38(2):101-120. <https://doi.org/10.47717/turksurg.2022.5757>
- Deo KB, Kumar R, Tiwari G, Kumar H, Verma GR, Singh H. Surgical management of hepatic hydatid cysts – conservative versus radical surgery. *HPB (Oxford)* 2020;22(10):1457-1462. <https://doi.org/10.1016/j.hpb.2020.03.003>

Accepted 24 April 2024.